

# Role of multi-slice computed tomography in the recognition of pericardial cyst

Rafał Młynarski<sup>1,2</sup>, Rafał Gardas<sup>1</sup>, Agnieszka Młynarska<sup>1,2</sup>,  
 Włodzimierz Kargul<sup>1</sup>, Michał Tendera<sup>3</sup>, Maciej Sosnowski<sup>2,3</sup>

<sup>1</sup>Department of Electrocardiology, Upper-Silesian Medical Centre, Katowice, Poland

<sup>2</sup>Unit of Noninvasive Cardiovascular Diagnostics, Upper-Silesian Medical Centre, Katowice, Poland

<sup>3</sup><sup>rd</sup> Division of Cardiology, Medical University of Silesia, Katowice, Poland

## Abstract

*A pericardial cyst is, according to the definition, a collection of fluid or blood in the pericardial space (inside the pericardial sac) around the heart. New visualization methods can help in the non-invasive diagnosis of pericardial cysts. Based on a presented case, we conclude that multi-slice computed tomography can have a great impact on the detection of pericardium diseases such as a pericardial cyst. (Cardiol J 2011; 18, 1: 90–91)*

**Key words:** pericardial cyst, pericardium, computed tomography

The pericardium is difficult to evaluate. New visualization methods can help in non-invasive diagnosis of diseases of the pericardium. One of the commonest diseases is a pericardial cyst [1]. According to the definition, this is a collection of fluid or blood in the pericardial space (inside the pericardial sac) around the heart. There are a number of causes, which can include congestive heart failure, cancer and autoimmune disease. Rarely, the cause can be perforation of the endocardial leads [2–4].

A 68 year-old patient with coronary artery disease, after myocardial infarction, was implanted in September 2002 with a dual chamber implantable cardioverter-defibrillator (Medtronic GEM II DR) in secondary prevention due to sustained ventricular tachycardia. At that time, ejection fraction (EF) was 40% and there was no fluid in the pericardium by echocardiography (GE, Vivid 7, USA). Three years after implantation, the patient was hospitalized due to cardiac decompensation. In the echo

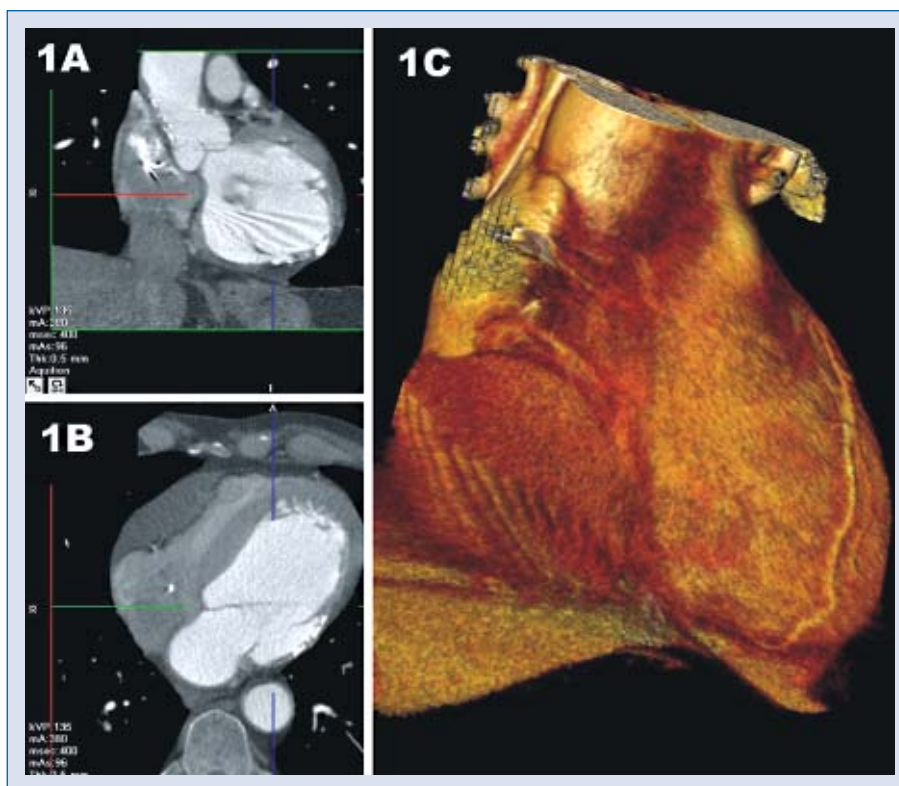
exam, EF had dropped to about 30% and there was a large amount of fluid around the right ventricle (RV) — in systole 32 mm, without clinical evidence of cardiac tamponade. A suspicion of late lead perforation was ruled out by the chest X-ray, echo exam and control of the implantable cardioverter-defibrillator (ICD) system. The patient was treated with steroid and non-steroid anti-inflammatory drugs. During the hospital stay, and subsequent follow-up visits, the fluid level in the pericardium was stable and the patient's condition good. In May 2006, the patient was admitted for planned ICD replacement. Even though the fluid level around RV assessed by echo was 45 mm, the patient was in a good clinical condition with no complaints.

Because we could not thoroughly visualize the pericardium by echocardiography, a 64-slice computed tomography (CT) was performed, using an Aquilion 64 scanner (Toshiba Medical Systems, Japan). Scanning with a retrospective ECG-gating was performed using a 64 slice with a collimated slice

**Address for correspondence:** Rafał Młynarski, MD, PhD, Department of Electrocardiology, Upper-Silesian Medical Center, Ziółowa 45/47, 40–635 Katowice, Poland, tel: +48 32 359 88 93, fax: +48 32 2524098, e-mail: Rafal\_Mlynarski@mp.pl

Received: 19.01.2010

Accepted: 14.02.2010



**Figure 1.** Pericardial cyst: **A, B.** Computed tomography multi planar reformatting (CT MPR) in two-dimensional, segment: 780 ms; layer: 0.5 mm; **C.** Three-dimensional reconstruction of the heart including the cyst.

thickness of 0.5 mm during a breath-hold. Images were reconstructed at 40% R-R wave interval. All analyses were performed both in two-dimensional (2D) multi planar reformatting (MPR) and three-dimensional (3D) volume rendering reconstructions. Helical pitch was 12.8 (best mode) and rotation time was 0.4 s. Average tube voltage was 135 kV at 380 mA.

In Figures 1A, B, tomographic images in MPR in 2D are presented. 3D reconstruction can be seen in Figure 1C. The structure distanced from surrounding tissues is clearly visible. Slightly compressed right ventricle and right atrium can be observed. Measurements in multi-slice computed tomography were in diastole a cyst 40 mm wide and 216 mm long. Based on the images and clinical symptoms, a pericardial cyst was recognized.

Because of the high perioperative risk, the patient was not qualified for cardiosurgical treatment. During follow-up visits, the patient's condition was stable and the fluid level diminished. In the last echo exam, there was 18 mm around the right ventricle. Through whole the follow-up period, the ICD function was correct.

## Conclusions

Based on the presented case, we conclude that multi-slice computed tomography has a great impact on the early detection of pericardium diseases such as pericardial cyst.

## Acknowledgements

The authors do not report any conflict of interest regarding this work.

## References

1. Cioffi U, De Simone M, Ciulla MM. Computed tomography and endoscopic ultrasound in detection and characterization of mediastinal masses. *J Thorac Cardiovasc Surg*, 2008; 136: 1606.
2. Modi S, Chenzbraun A, Fewins H, Binukrishnan S, Ramsdale DR. Giant asymptomatic pericardial cyst. *J Cardiovasc Med*, 2009; 10: 646–648.
3. Ogah OS, Akisanya CO, Timeyin AO, Adebisi AA, Adebo OA. A large pericardial cyst presenting with severe chest pain: A case report and review of literature. *Afr J Med Med Sci*, 2009; 38: 83–86.
4. Elamin WF, Hannan K. Pericardial cyst: an unusual cause of pneumonia. *Cases J*, 2008; 1: 26.