

Conus Artery in Coronary CT Angiography

Agnieszka Mlynarska^{1,2,3,*}; Rafal Mlynarski^{1,2}; Maciej Sosnowski^{1,4}

¹Unit of Noninvasive Cardiovascular Diagnostics, Medical University of Silesia, Katowice, Poland

²Department of Electrophysiology, Upper Silesian Cardiology Center, Katowice, Poland

³Unit of Internal Nursing, Medical University of Silesia, Katowice, Poland

⁴Division of Cardiology, Medical University of Silesia, Katowice, Poland

*Corresponding author: Agnieszka Mlynarska, Unit of Noninvasive Cardiovascular Diagnostics, Unit of Internal Nursing and Department of Electrophysiology, Upper Silesian Cardiology Center, Medical University of Silesia, Katowice, Poland. Tel: +48-32606484161, Fax: +48-32322524098, E-mail: agnieszka.wlodzyka@o2.pl

Received: April 22, 2014; Revised: May 9, 2014; Accepted: May 12, 2014

Background: The conus artery is usually the first branch of the right coronary artery (RCA) and passes around the right ventricular outflow tract.

Objectives: To examine whether it is possible to visualize the conus artery in multi-slice computed tomography (CT).

Patients and Methods: In 79 consecutive patients (aged 56 ± 12.9 years; 13 women), 64-slice CT was performed due to a suspicion of coronary artery disease. The standard protocol for scanning with retrospective gating was used for all the patients.

Results: It was possible to visualize the conus artery in coronary CT angiography in 64 (81%) patients. The course of the conus artery in the right ventricle was commonly in the outflow tract direction. The conus artery was visualized at a distance of 33.2 ± 16.3 mm. The average diameter of the conus artery was 2.3 ± 0.8 mm. The conus artery most frequently originated from the first segment of the right coronary artery (53%) and directly from the aorta (37.9%). In the rest of the cases, there was a common trunk for both vessels (CA/RCA).

Conclusions: In most cases, the conus artery can be visualized in cardiac CT. A description of the conus artery should be a part of the standard clinical coronary CT angiography description.

Keywords: Arteries; Tomography, Spiral Computed; Angiography; Coronary Vessels

1. Background

The right coronary artery (RCA) begins in the right sinus of Valsalva and courses through the right atrioventricular groove (coronary sulcus) between the right atrium (RA) and the right ventricle (RV). The final part of this artery in most subjects is called "the posterior descending artery". However, the posterior descending artery is not always a branch of the RCA because sometimes it starts from the left circumflex artery (LCx) or from both RCA and LCx (e.g. in co-dominant coronary circulation).

The conus artery is usually the first branch of the RCA which passes around the right ventricular outflow tract (RVOT) and supplies it with blood (1). It is sometimes called "the third coronary artery" and can be an important backup artery in the case of the stenosis of the left anterior descending artery (LAD) (1-3). The conus artery has occasionally been noted as a source of collateral blood flow (4).

2. Objectives

New imaging techniques can noninvasively visualize the conus artery. Cardiac computed tomography (CT), which offers the possibility to visualize the human anat-

omy, can facilitate the imaging (5), but the question still remains: is CT useful to visualize the conus artery?

3. Materials and Methods

Seventy-nine consecutive patients (aged 56 ± 12.9 years; 13 women) were examined using noninvasive coronary angiography according to the current appropriateness criteria. Patients were excluded if they presented with the following clinical conditions: atrial fibrillation (permanent or persistent); frequent cardiac extrasystoles; renal insufficiency (glomerular filtration rate < 60); hyperthyreosis; known allergy to non-ionic contrast agents; and a previously implanted pacemaker with unipolar leads.

3.1. Computed Tomography Protocol

A 64-slice multi-slice computed tomography (MSCT) of the heart was performed using an Aquilion 64 scanner (Toshiba Medical Systems, Tochigi, Japan). Scanning with retrospective electrocardiography (ECG)-gating was performed using a 64-MSCT with a collimated slice thickness of 0.5 mm during a breath-hold. The helical pitch was 12.8 (best mode) and rotation time was 0.4 seconds. The av-

Implication for health policy makers/practice/research/medical education:

The conus artery is usually the first branch of the right coronary artery and passes around the right ventricular outflow tract. We herein document the possibility of visualizing the conus artery in cardiac computed tomography (CT). In our opinion, a description of the conus artery should be a part of the standard coronary CT angiography description.

Copyright © 2014, Iranian Society of Echocardiography; Published by Kowsar Corp. This is an open-access article distributed under the terms of the Creative Commons Attribution License, which permits unrestricted use, distribution, and reproduction in any medium, provided the original work is properly cited.

erage tube voltage, which was strictly dependent on the patient's body mass index, was 120 kV at 380 mA.

All reconstructions were created in the optimal phase for coronary arteries (typical 70-80 and sometimes 90% RR interval), for each of which, three high-quality reconstructions were created. In some cases, additional reconstructions were also performed thanks the retrospective method of gating. The cut-off for heart rate was 65 beats per minute as. If the heart rate was higher, Metoprolol succinate (Betaloc, Astra Zeneca, Sweden) at a dose of 5-10 mg was administered intravenously, if not contraindicated. If the expected slowing of the heart rate was not achieved, the patient was excluded from the study. On average, 100 mL of non-ionic contrast medium, containing Iopromide (Ultravist 370, Bayer Schering Pharma AG, Germany) as the active ingredient, was administered to each patient during the examination at an average rate of 5.0 mL/s. The contrast was administered in three standard phases (6).

3.2. Measurements

Measurements and the search for the conus artery, including grading, were performed using a Vitrea 2 workstation (Vital Images, Minnetonka, Minnesota-USA; software version 3.9.0.0). All the data were evaluated by two experienced MSCT investigators. Three-dimensional volume rendering and two-dimensional maximum intensity projection (MIP) and multi-planar reconstruction (MPR) reconstructions (thickness 0.5-2.5 mm) were created on the conus artery and the proximal part (segments one and two) of the RCA. All the measurements were performed on a two-dimensional MIP. The optimal reconstruction from the three highest quality ones was chosen.

The following features of the conus artery were analyzed in the MSCT images (including quantitative values): 1) number of branches (if they existed); 2) origin (RCA, common trunk with RCA, and right sinus of Valsalva); 3) length from the RCA ostium (in case of originating from RCA and from right sinus of Valsalva); 4) course (RVOT, LAD, and other); 5) length of the visualized part (in mm); and 6) average diameter (in mm).

Cardiac hemodynamic parameters were evaluated using semi-automatic software on a Vitrea 2 (Vital Images) workstation.

4. Results

The characteristics of the patients included according to their left ventricular systolic function are presented in Table 1. It was possible to visualize the conus artery in cardiac CT in 64 (81%) patients. The course of the conus artery was commonly in the RVOT direction near the LAD. No connections were found between the conus artery and the LAD in our study population. The conus artery was visualized at a distance of 33.2 ± 16.3 mm: the minimum length was 5 mm and the maximum was 68 mm. The average diameter of the conus artery was 2.3 ± 0.8 mm.

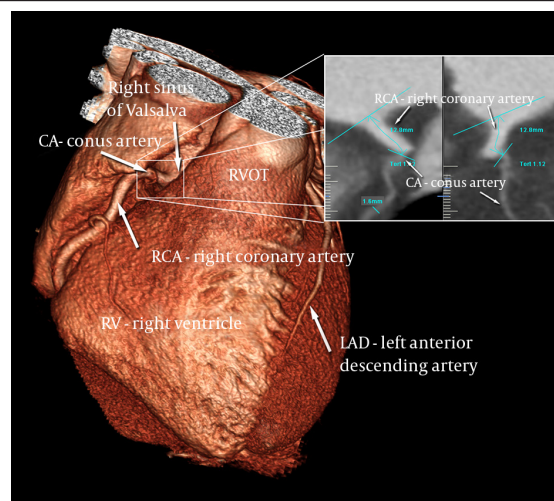


Figure 1. Conus Artery Coming from the Right Coronary Artery

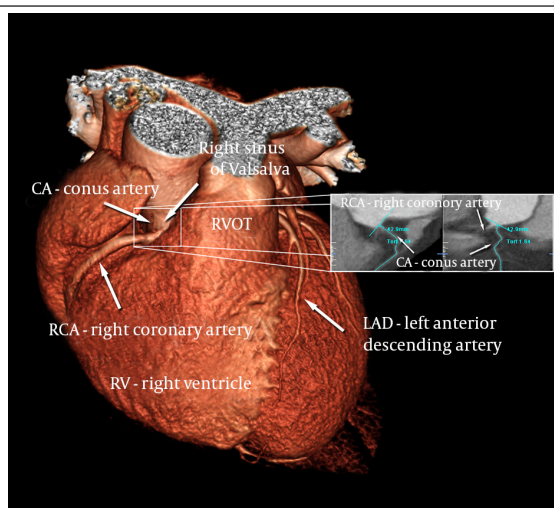


Figure 2. Separate from the Right Coronary Artery, the Conus Artery Comes from the Right Sinus of Valsalva (Directly from the Aorta)

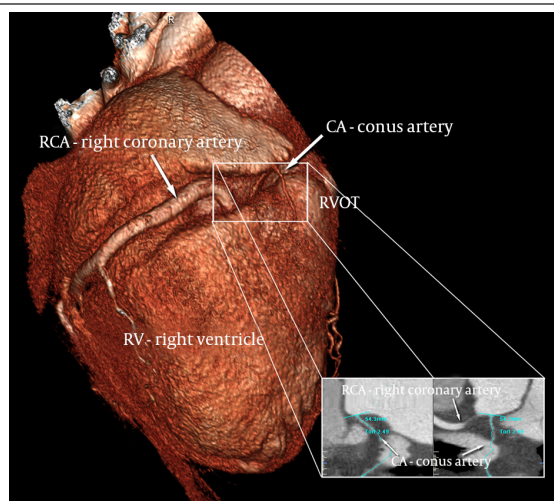


Figure 3. Common Trunk of the Right Coronary Artery and the Conus Artery in the Area of the Sinus of Valsalva

Table 1. Characteristics of the Included Patients (n = 79)

Characteristics	
Hemodynamic Parameters	
Ejection fraction, %	Mean ± SD 62.5 ± 10.9
End-systolic volume, mL	153.8 ± 45.2
End-diastolic volume, mL	61.0 ± 33.8
Stroke volume, mL	92.8 ± 21.8
Cardiac output, L/min	5.7 ± 1.4
Risk factors	
Hypercholesterolemia	Count (%) 60 (76)
Hypertension	76 (96)
Diabetes	13 (16)
Smoking	44 (56)

The minimum diameter of the analyzed vessel was 0.8 mm and maximum 5.2 mm.

Sometimes, the vessel was so small that a better visualization (sometimes the only possible one) was on 2D MIP: such a situation occurred in 26 of the 79 cases (32.9%). Three-dimensional images are not usually good for the visualization of the conus artery.

In the most frequent anatomical variant (53% of all), the conus artery started from the first segment of the RCA (Figure 1). The average length of the RCA to the origin of the conus artery was 12.9 ± 8.53 mm (range = 1-39 mm). In that case, the vessel was visualized at a distance of 30.2 ± 16.8 mm (range = 5-68 mm). The average diameter was 2.4 ± 0.9 mm (range = 0.8-5 mm).

The second most frequent variant was when it originated from the right sinus of Valsalva directly from the aorta: this variant occurred in 30 (37.9%) of the patients (Figure 2). The average distance between the RCA and the conus artery in the case of a separate point of origin was 5.7 ± 9.3 mm (range = 0-51 mm). In that case, the vessel was visualized at a length of 36.6 ± 15.3 mm (range = 11-64.6 mm) and the average diameter of the conus artery was 2.2 ± 0.8 mm (range = 1.5-3.1 mm). The rarest variant of the RCA/conus artery was a common trunk for both vessels: it was found in 11 (14%) of the cases (Figure 3). This is a sub-variant for situations when the conus artery originates from the right sinus of Valsalva. In such a situation, the conus artery was visualized at a length of 47.6 ± 10.3 mm and the average diameter of the conus artery was 2.5 ± 0.5 mm.

5. Discussion

The prognosis of patients with coronary artery disease depends on the presence, size, or even shape of the collateral circulation (7). One of the most frequent, but underestimated, types of collateral circulation is the presence of the conus artery (1). This artery usually starts in the area of the right sinus of Valsalva and runs in the direction of the RVOT.

In the literature on this subject, there have been a few

postmortem studies in which the authors try to prove that the conus artery exists. Sankari et al. (8) examined 30 cadaveric hearts and 20 angiograms and showed that the most frequent occurrence was a single ostium from the right sinus of Valsalva/RCA (23.30%; 76.7%) and the double ostium, which indicated the RCA and the conus artery (5.30%; 16.7%). In our study, the frequencies were 41 (52%) and 30 (38%), respectively. On the other hand, the patterns of the origin of the conus artery were aortic (7.30%; 23.3%), common origin (7.30%; 23.3%), and the RCA (16.30%; 53.3%) (8). In our study, these rates were 3 (4%), 11 (14%), and 41 (52%), respectively. The authors concluded that the existence of the right conus artery acts as a bridge for the collateral circulation between the right and left coronary systems, which is significant in the ischemic changes of the heart (8).

A similar postmortem investigation is the Lujinovic et al. (3) study, in which the authors examined 25 adult human hearts to identify the arteries and their origin, course, branching and present anastomoses. Eight out of the 25 hearts (32%) that were examined had a conus artery. The authors concluded that the most suitable term to identify the supernumerary heart artery that originates independently from the right sinus of Valsalva is the third coronary artery. The third coronary artery represents a significant path for the collateral coronary circulation as it often anastomoses with the LAD. Both of these anatomical studies documented the presence of a conus artery in cadaveric hearts. It was only a matter of time before in vivo studies were prepared. The largest such study was carried out by Levin et al. (9). Among the 508 cases in which coronary angiography was performed, the conus artery was adequately visualized in 80.5% (64 (81%) in our study). Inadequate visualization occurred in 4.3% and non-visualization occurred in 15.2% (8 (10%) in our study). They also found two anatomic variants of the conus artery in a small number of cases. The first variant was a huge conus artery that originated from the first segment of the RCA and supplied not only the RVOT but also the anterior free wall of the RV. In our study, we were not able to visualize the distal parts of the conus artery; the average visualization length was 31.4 mm. In the second variant presented by Levin's group, the conus branch arose from the LAD rather than from the RCA. In our study, we did not find such a variant. Both studies describe the conus artery in a different way: we used noninvasive cardiac CT, whereas Levin et al. analyzed coronary cine-arteriograms.

Although MSCT examinations have become very popular, only a few reports exist about the visualization of the coronary artery in coronary CT angiography. In 2010, de Agustin et al. (10) published a report in which they described 3 patients with advanced coronary artery disease where the collateral flow was provided to the LAD by a large diameter conus artery. The authors confirmed the usefulness of CT for the study of distal beds in patients with coronary occlusion. CT was also recognized as a good method for studying the collateral circulation, especially when there is a conflict between the findings of the coronary angiography and the

ventricular function.

The existing literature also contains some case reports. Wynn et al. (4) presented a case in which the collateral flow to the occluded LAD originated from the conus branch as demonstrated in a stress echocardiographic examination. In that case report, the importance of the conus artery was described in its responsibility for the relative preservation of the function in the affected segments of the LAD. Another case in which the LAD was occluded was reported by Kawamura A et al. (11). The authors used MSCT to confirm that the conus artery originates directly from the aorta and provides sufficient collateral support to the LAD. Importantly, a percutaneous coronary intervention of the LAD was successfully performed using a contralateral injection via the isolated conus artery (11). Both of these cases confirmed the practical role of the visualization of the conus artery by means of various diagnostic methods, including cardiac CT. Our study also confirms the applicability of cardiac CT for the visualization of the conus artery and describes the basic anatomy of the conus artery. The new types of CT scanners that offer a higher image quality with a smaller dose of radiation can help visualize the conus artery even better than is documented in our study.

According to the current recommendations, coronary CT angiography was performed in symptomatic patients with an intermediate probability of coronary artery disease. In most individuals, no flow-limiting plaques were discerned. If a supportive role is considered for the conus artery, it is not surprising that its anastomosis with the LAD is not visualized. It remains to be fully elucidated whether the presence of significant stenosis would influence the development of such an anastomosis to provide blood flow support. Novel approaches, including CT-based fractional flow reserve estimation, might help answer this question (12).

5.1. Limitations of the Study

Despite its relatively small size, our study is one of the largest of its kind to succeed in visualizing the conus artery using CT. The biggest limitation of this paper is, however, its lack of clinical reference. Indeed, we did not address what role the conus artery can play during specific clinical situations. Thus, further research (including big cohort studies) is necessary in order to evaluate the importance of the conus artery and, more importantly, to determine which type of this vessel can potentially be useful for the diagnosis and treatment of coronary artery disease.

In most cases, the conus artery can be visualized by

cardiac CT. A description of the conus artery should be a part of the standard clinical coronary CT angiography description. In our research, the conus artery was present in almost all of the patients, and it commonly originated from segment one of the RCA.

Acknowledgements

The authors are indebted to the radiology technicians for their technical support.

References

- Schlesinger MJ, Zoll PM, Wessler S. The conus artery: a third coronary artery. *Am Heart J*. 1949;**38**:823–38.
- Edwards BS, Edwards WD, Edwards JE. Aortic origin of conus coronary artery. Evidence of postnatal coronary development. *Br Heart J*. 1981;**45**(5):555–8.
- Lujinovic A, Ovcina F, Tursic A. Third coronary artery. *Bosn J Basic Med Sci*. 2008;**8**(3):226–9.
- Wynn GJ, Noronha B, Burgess MI. Functional significance of the conus artery as a collateral to an occluded left anterior descending artery demonstrated by stress echocardiography. *Int J Cardiol*. 2010;**140**(1):e14–5.
- Taylor AJ, Cerqueira M, Hodgson JM, Mark D, Min J, O'Gara P, et al. ACCF/SCCT/ACR/AHA/ASE/ASNC/NASCI/SCAI/SCMR 2010 appropriate use criteria for cardiac computed tomography. A report of the American College of Cardiology Foundation Appropriate Use Criteria Task Force, the Society of Cardiovascular Computed Tomography, the American College of Radiology, the American Heart Association, the American Society of Echocardiography, the American Society of Nuclear Cardiology, the North American Society for Cardiovascular Imaging, the Society for Cardiovascular Angiography and Interventions, and the Society for Cardiovascular Magnetic Resonance. *J Am Coll Cardiol*. 2010;**56**(22):1864–94.
- Mlynarski R, Sosnowski M, Wlodyka A, Chromik K, Kargul W, Tendera M. Optimal image reconstruction intervals for noninvasive visualization of the cardiac venous system with a 64-slice computed tomography. *Int J Cardiovasc Imaging*. 2009;**25**(6):635–41.
- Meier P, Seiler C. The coronary collateral circulation—clinical relevances and therapeutic options. *Heart*. 2013;**99**(13):897–8.
- Udaya Sankari T, Vijaya Kumar J, Saraswathi P. Anatomy the anatomy of right conus artery and its clinical significance. *Rec Res Sci Technol*. 2011;**3**(10):30–9.
- Levin DC, Beckmann CF, Garnic JD, Carey P, Bettmann MA. Frequency and clinical significance of failure to visualize the conus artery during coronary arteriography. *Circulation*. 1981;**63**(4):833–7.
- de Agustin JA, Marcos-Alberca P, Hernandez-Antolin R, Vilacosta I, Perez de Isla L, Rodriguez E, et al. Collateral circulation from the conus coronary artery to the anterior descending coronary artery: assessment using multislice coronary computed tomography. *Rev Esp Cardiol*. 2010;**63**(3):347–51.
- Kawamura A, Jinzaki M, Kuribayashi S. Percutaneous revascularization of chronic total occlusion of left anterior descending artery using contralateral injection via isolated conus artery. *J Invasive Cardiol*. 2009;**21**(5):E84–6.
- Min JK, Leipsic J, Pencina MJ, Berman DS, Koo BK, van Mieghem C, et al. Diagnostic accuracy of fractional flow reserve from anatomic CT angiography. *JAMA*. 2012;**308**(12):1237–45.